

CASE REPORT

Misdiagnosed behavior change revealing fatal primitive intra-cerebral echinococcosis

Salem Bouomrani^{1,2*} Karama Regaieg³ Nesrine Belgacem¹ Oussema Souissi¹
Mouna Guermazi^{1,2} Sami Krimi³

Abstract: Central nervous system involvement in hydatidosis is rare compared to other somatic localizations: 1-5%. It is schematically divided into two major types: cerebral involvement and spinal involvement. The brain is a rare localization of hydatid cyst accounting for only 2% of all hydatid disease. The psychiatric manifestations revealing cerebral hydatidosis remain exceptional and often unrecognized and neglected by practitioners despite their potential severity. We report two original observations of fatal cerebral hydatidosis revealed by behavior change (psychomotor agitation, aggressiveness, persecutory delusion, and auditory and visual hallucinations) insufficiently explored in two women aged 45 and 17. The possibility of cerebral hydatidosis must always be evoked in front of any psychiatric symptomatology that remains unexplained in endemic areas for echinococcosis.

Keywords: behavior change, psychiatric manifestations, hydatid cyst, brain hydatidosis, intra-cerebral echinococcosis

1 Introduction

Echinococcosis is the most common cestode in the world with a predilection for the Middle East and North Africa.^[1-3] It is still one of the so-called “neglected” tropical diseases^[1] and represents a real public health problem as well as a heavy socio-economic burden in several countries of the world.^[1,3,4]

The world’s major endemic regions are the Mediterranean Basin, South America, Asia, including India, Afghanistan, Iran and Turkey; and parts of East Africa.^[1-3] Indeed the total number of infested subjects is estimated at 2-3 million worldwide^[5] and the severity of this disease lies mainly in its acute complications (rupture, superinfection, anaphylactic shock, *etc.*) with a risk of sudden death attributed to this parasitosis which remains today “serious and not exceptional”.^[6] This mortality mainly affects young people.^[5,6]

Brain localizations are part of the so-called unusual or aberrant localizations of this parasitosis (extra-hepatic and extra-pulmonary) observed in less than 10% of cases.^[7,8] The psychiatric manifestations revealing cerebral hydatid cyst remain exceptional and often unrecognized and neglected by practitioners despite their potential severity.^[9]

We report two original observations of fatal cerebral hydatidosis revealed by behavior change insufficiently explored.

2 Case 1

A woman aged 45 was found dead in her bed in the morning. Her medical history noted that she had been followed for two months for behavioral disorders, family aggression, persecutory delusion and auditory and visual hallucinations of progressive installation. No particular personal or family psychiatric history, drug or substance abuse, or any particular addictive behavior was noted. The somatic examination as well as the basic biological tests requested by her psychiatrist revealed no anomalies. The treatment with neuroleptics prescribed by her psychiatrist was ineffective. Given the unexplained nature of the death, an autopsy was indicated. Postmortem cerebral CT showed a large cerebral mass, of fluid density, intra-parenchymal, supratentorial, occupying the left parieto-occipital lobe, resulting in intracranial hypertension and subfalcine herniation (Figure 1).

Received: April 12, 2019 Accepted: May 21, 2019 Published: May 27, 2019

* Correspondence to: Salem Bouomrani, Department of Internal medicine, Military Hospital of Gabes, Gabes 6000, Tunisia; Sfax Faculty of Medicine, University of Sfax, Sfax 3029, Tunisia; Email: salembouomrani@yahoo.fr

¹ Department of Internal medicine, Military Hospital of Gabes, Gabes 6000, Tunisia

² Sfax Faculty of Medicine, University of Sfax, Sfax 3029, Tunisia

³ Department of Forensic Medicine, Gabes Regional Hospital, Gabes 6000, Tunisia

Citation: Bouomrani S, Regaieg K, Belgacem N, *et al.* Misdiagnosed behavior change revealing fatal primitive intra-cerebral echinococcosis. *Adv Health Behav.*, 2019, 2(1): 62-65

Copyright: © 2019 Salem Bouomrani, *et al.* This is an open access article distributed under the terms of the [Creative Commons Attribution License](https://creativecommons.org/licenses/by/4.0/), which permits unrestricted use, distribution, and reproduction in any medium, provided the original author and source are credited.

The post mortem examination concluded to a broken giant cerebral hydatid cyst. No other anomalies or other associated hydatid localizations were found. The search for toxic substances in the blood and gastric fluid was negative.

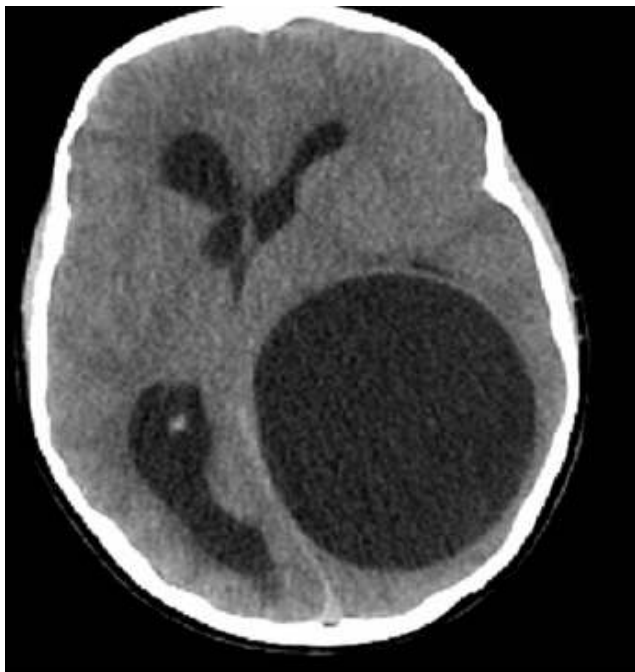

Figure 1. Axial cerebral CT: large left parieto-occipital mass of fluid density with intracranial hypertension and subfalcine herniation

3 Case 2

A 17-year-old teenage girl who died suddenly in the emergency room where she was seen for severe acute headaches associated with vomiting.

The interrogation of the family revealed the notion of brutal and unexplained change in her behavior for a month, particularly with psychomotor agitation, aggression towards other family members, and persecutory delusion. She was examined by a psychiatrist and treated with anti-psychotic drugs but without any improvement. No particular family or personal psychiatric history was revealed. Similarly, no recent traumatic event or specific drug or toxic intake has been reported.

Postmortem cerebral CT showed a large multivesicular cerebral mass, of fluid density, intra-parenchymal, supratentorial, occupying the right parieto-occipital lobe and complicated by cranial deformation, intracranial hypertension and a significant mass effect on midline structures (Figure 2).

The autopsy revealed an enormous cerebral hydatid cyst (Figure 3 and Figure 4). No other hydatid local-

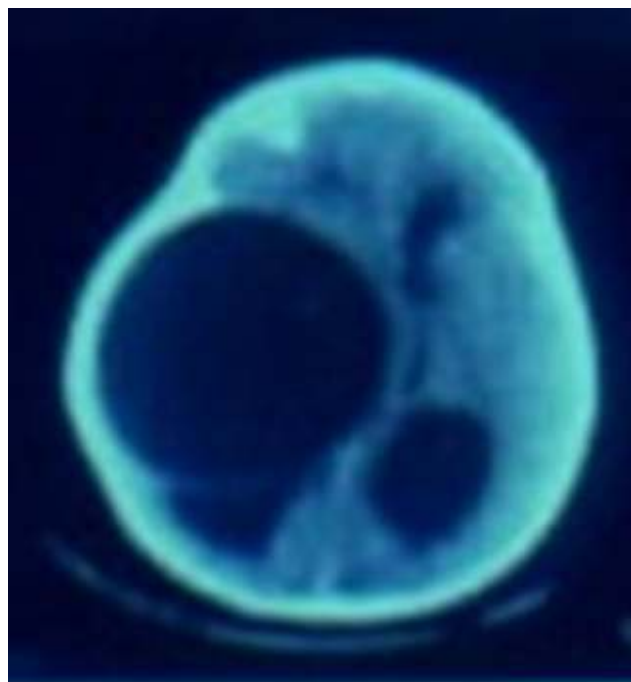


Figure 2. Axial cerebral CT: bulky right parieto-occipital multi-vesicular mass, deforming the skull, complicated with intracranial hypertension and a significant mass effect

izations were found. The search for toxic substances in the blood and gastric fluid was negative.

4 Discussion

Unusual localizations of human hydatid disease can affect all tissues and organs: the gastrointestinal tract, pancreas, spleen, urogenital system, retroperitoneum, peripheral nervous system, bones, endocrine glands, eyeball, heart, soft tissues ... etc.^[7-14]

Central nervous systems involvement in hydatidosis is rare compared to somatic locations: 1-5%.^[7-9] It is schematically divided into two major types: cerebral involvement and spinal (spinal cord) involvement. Brain localization was found in 69.2% of central nervous system cases of hydatidosis whereas spinal involvement was found in 30.8%.^[15,16]

The brain is a rare localization of hydatid cyst accounting for only 2% of all hydatid disease^[17] and cerebral hydatidosis occupies a significant place among intracranial expansive processes: 3.6%.^[18]

Concerning age distribution, children have a significantly higher frequency: from 50 to 93%.^[18] This could be explained by the permeability of the ductus arteriosus during the neonatal period allowing the parasite to move from the periphery to the brain.^[19] There is no significant difference according to sex, but a slight male predominance is found in a few series.^[20] Our two cases are

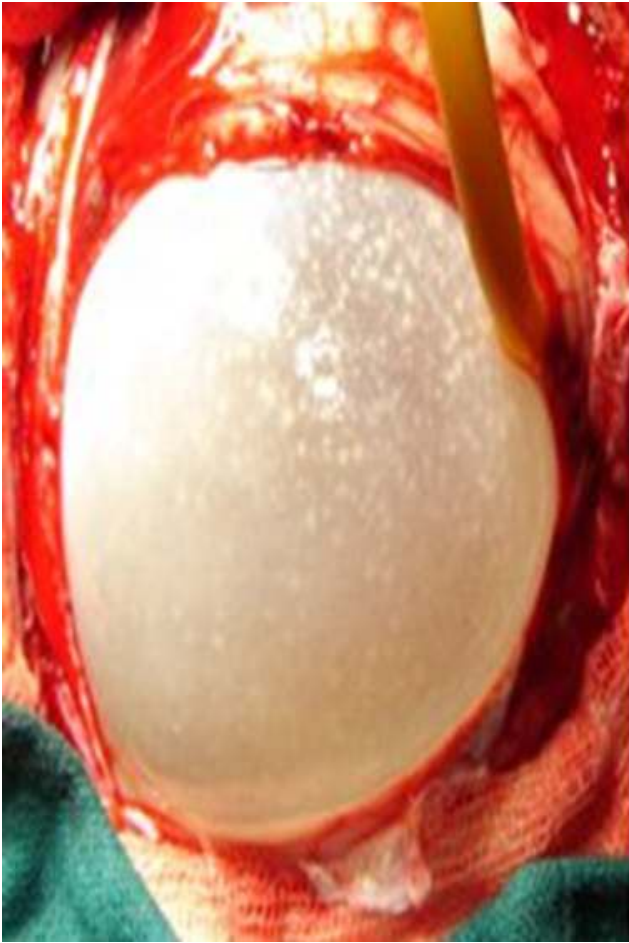

Figure 3. Macroscopic appearance of the giant cerebral hydatid cyst at the opening of the cranial vault

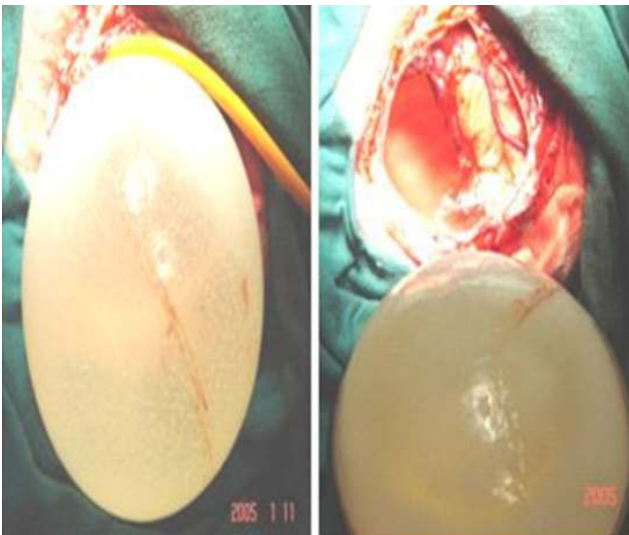


Figure 4. Macroscopic appearance of cerebral hydatid cyst after excision

distinguished by the female sex and late onset in adulthood.

The hydatid disease can reach any part of the brain but the hemispheres are the preferential localization: 95% of the cases.^[21] The cysts are generally located in the supratentorial region in the territory of the middle cerebral artery: the temporo-parieto-occipital region.^[22]

The clinical presentation of the hydatid cyst of the brain is similar to that of a brain tumor. It depends on the localization, size and number of cysts. The patient has focal neurological signs (motor deficits such as hemiplegia or hemiparesis, cerebellar syndrome, seizures, disturbances of consciousness) and/or symptoms related to intracranial hypertension (diffuse headaches relieved by jet vomiting and accompanied by visual disturbances).^[9,23] Psychiatric manifestations can be noted in 15 to 20% of cases of cerebral hydatid cyst, particularly at the beginning of their development.^[9] These manifestations are nonspecific and are often overlooked and neglected by clinicians.^[9,24,25]

Several types of behavior disorders have been reported: instability, agitation, violence, aggression, isolation, corporo-sartorial carelessness, visual and auditory hallucinations, schizophrenia-like syndrome, subconfusion, sleep disorders, hostility, emotional lability, persecutory delusion, hypothalamic stupor, and infantilism.^[9,24,25]

Hyper eosinophilia is rarely found. Similarly, hydatid serology is characterized by low sensitivity in this location; it is rather beneficial for post-operative surveillance to detect recurrences.^[16,18,23]

The diagnosis of cerebral hydatid cyst by medical imaging (CT and MRI) is generally easy and rarely raises a problem of differential diagnosis since the appearance of cerebral hydatidosis is almost pathognomonic.^[21,26,27]

The treatment of cerebral hydatid cyst is mainly surgical. However, the use of the anthelmintic agent albendazole is recommended to: sterilize the cyst, reduce the risk of anaphylaxis, reduce the cyst wall stress and decrease the post-operative recurrence

5 Conclusion

Human hydatid disease of the central nervous system is rare even in endemic areas. The primary brain localization is exceptional and is characterized by a high clinical latency. The psychiatric manifestations associated with these locations are not as rare as thought, but are unknown to clinicians. Our two observations are characterized by the female sex, the late onset in adulthood, the revelation by psychiatric symptoms, and the fatal evolution. The possibility of cerebral hydatidosis must al-

ways be evoked in front of any psychiatric symptomatology that remains unexplained in endemic areas for echinococcosis.

References

- [1] Hotez PJ, Savioli L and Fenwick A. Neglected tropical diseases of the Middle East and North Africa: review of their prevalence, distribution, and opportunities for control. *PLoS Neglected Tropical Diseases*, 2012, **6**(2): e1475. <https://doi.org/10.1371/journal.pntd.0001475>
- [2] Dakkak A. Echinococcosis/hydatidosis: a severe threat in Mediterranean countries. *Veterinary Parasitology*, 2010, **174**(1-2): 2-11. <https://doi.org/10.1016/j.vetpar.2010.08.009>
- [3] Sadjjadi SM. Present situation of echinococcosis in the Middle East and Arabic North Africa. *Parasitology International*, 2006, **55** Suppl: 197-202. <https://doi.org/10.1016/j.parint.2005.11.030>
- [4] Majorowski MM, Carabin H, Kilani M, et al. Echinococcosis in Tunisia: a cost analysis. *Transactions of the Royal Society of Tropical Medicine & Hygiene*, 2005, **99**(4): 268-278. <https://doi.org/10.1016/j.trstmh.2004.06.011>
- [5] Ben Khelil M, Allouche M, Banasr A, et al. Sudden death due to hydatid disease: a six-year study in the northern part of Tunisia. *Journal of Forensic Sciences*, 2013, **58**(5): 1163-1170. <https://doi.org/10.1111/1556-4029.12172>
- [6] Jedidi M, Mlayeh S, Masmoudi T, et al. Sudden death due to hydatid cyst: thirty-four medicolegal autopsy cases. *Am J Forensic Med Pathol*, 2014, **35**(1): 29-33. <https://doi.org/10.1097/PAF.0000000000000064>
- [7] Keser SH, Selek A, Ece D, et al. Review of Hydatid Cyst with Focus on Cases with Unusual Locations. *Turk Patoloji Derg*, 2017, **33**(1): 30-36. <https://doi.org/10.5146/tjpath.2016.01369>
- [8] Kirei DA, Karabacakolu A, Odev K, et al. Uncommon locations of hydatid cysts. *Acta Radiologica*, 2003, **44**(6): 622-636. <https://doi.org/10.1080/02841850312331287749>
- [9] Asri F, Tazi I, Maaroufi K, et al. Cerebral hydatid cyst and psychiatric disorders. Two cases. *Lencephale*, 2007, **33**(2): 216-219. [https://doi.org/10.1016/S0013-7006\(07\)91553-5](https://doi.org/10.1016/S0013-7006(07)91553-5)
- [10] Bouomrani S, Souissi O, Guermazi M, et al. An Unexpected Etiology of Myocardial Ischemia in Young. *Journal Of Hypertension And Cardiology*, 2019, **2**(4): 13-19. <https://doi.org/10.14302/issn.2329-9487.jhc-19-2719>
- [11] Bouomrani S and Feki W. Pancreatic and gastrointestinal hydatidosis. *Gastroenterol Hepatol Open Access*, 2019, **10**(2): 108-110.
- [12] Bouomrani S and Feki W. Humain Splenic Hydatidosis: A Review. *Gastroenterology and Hepatology International Journal*, 2019, **4**(1): 000146.
- [13] Bouomrani S, Souissi O, Regaïeg N, et al. Primary Hydatid Cyst of the Thyroid Gland Revealed by Primary Hypothyroidism. *Journal of Infectious Disease & Travel Medicine*, 2018, **2**(3): 000121.
- [14] Bouomrani S, Dabboussi S, Nefoussi M, et al. Juvenile Primary Mediastinal Hydatid Cyst. *EC Pulmonology and Respiratory Medicine*, 2018, **7**(11): 1-5.
- [15] Tizniti S, Allali N, El QA, et al. An unusual cerebral hydatid cyst. *Journal of Neuroradiology Journal De Neuroradiologie*, 2000, **27**(3): 200-202.
- [16] Limaiem F, Bellil S, Bellil K, et al. Primary hydatidosis of the central nervous system: a retrospective study of 39 Tunisian cases. *Clinical Neurology & Neurosurgery*, 2010, **112**(1): 23-28. <https://doi.org/10.1016/j.clineuro.2009.09.001>
- [17] Popli MB and Khudale B. Primary multiple hydatid cysts of the brain. *Australasian Radiology*, 1998, **42**(1): 90-91. <https://doi.org/10.1111/j.1440-1673.1998.tb00576.x>
- [18] Ciurea AV, Fountas KN, Coman TC, et al. Long-term surgical outcome in patients with intracranial hydatid cyst. *Acta Neurochirurgica*, 2006, **148**(4): 421-426. <https://doi.org/10.1007/s00701-005-0679-z>
- [19] Lunardi P, Missori P, Di Lorenzo N, et al. Cerebral Hydatidosis in Childhood: A Retrospective Survey with Emphasis on Long-term Follow-up. *Neurosurgery*, 1991, **29**(4): 515-518. <https://doi.org/10.1227/00006123-199110000-00005>
- [20] Khaldi M, Mohamed S, Kallel J, et al. Brain hydatidosis: report on 117 cases. *Child's Nervous System*, 2000, **16**(1011): 765-769. <https://doi.org/10.1007/s003810000348>
- [21] Abbassioun K, Amirjamshidi A and Sabouri Deylamie M. Hydatid Disease of the Central Nervous System Imaging Characteristics and General Features. *Iran Journal of Radiology*, 2003, **2**: 125-131.
- [22] Abdel Razek AAK, Watcharakorn A and Castillo M. Parasitic Diseases of the Central Nervous System. *Neuroimaging Clinics of North America*, 2011, **21**(4): 815-841. <https://doi.org/10.1016/j.nic.2011.07.005>
- [23] Tuzun Y, Kadioglu HH, Izci Y, et al. The Clinical, Radiological and Surgical Aspects of Cerebral Hydatid Cysts in Children. *Pediatr Neurosurg*, 2004, **40**(4): 155-160. <https://doi.org/10.1159/000081932>
- [24] Brage D, Pedace EA and Napolitano AG. Hypothalamic stupor caused by diencephalo-hypophysial hydatidosis (Cairns' akinetic mutism). *Revue Neurologique*, 1955, **93**(5): 730-739.
- [25] Fossati CJ. 4 cases of infantilism caused by hydatidosis. *Revista Clinica Espanola*, 1967, **107**(2): 128-130.
- [26] Tllili-Graïess K, El-Ouni F, Gharbi-Jemni H, et al. Cerebral hydatid disease: imaging features. *Journal of Neuroradiology Journal De Neuroradiologie*, 2006, **33**(5): 304-318. [https://doi.org/10.1016/S0150-9861\(06\)77288-1](https://doi.org/10.1016/S0150-9861(06)77288-1)
- [27] Demir K, Karsli AF, Kaya T, et al. Cerebral hydatid cysts: CT findings. *Neuroradiology*, 1991, **33**(1): 22-24. <https://doi.org/10.1007/BF00593328>