

## CASE REPORT

# Primary angiosarcoma of the breast: A clinical case and review of the literature

Lena Marinova<sup>1\*</sup> Bistra G. Yordanova<sup>2</sup> Doroteya V. Malinova<sup>3</sup>

**Abstract:** We present here a rare case of primary mammary angiosarcoma in 48-year-old female patient. After 3 years without treatment, the woman presented to the hospital with locally advanced tumor in right mammary gland, involving the overlying skin and bleeding. Radical mastectomy was performed with axillary lymph-node dissection. The CT scan revealed solitary liver metastasis. After an overview of different cases of primary angiosarcoma of the breast published in the literature, we discuss the importance of histological criteria and immunohistochemical methods, as well as the optimal multimodal treatment in these patients. Poorly differentiated primary mammary angiosarcoma (grade 3) is an invasive neoplasm with high risk of local recurrence and distant metastases. The multimodal treatment involves radical mastectomy with or without axillary lymph-node dissection. Adjuvant radiotherapy and adjuvant chemotherapy help the local tumor control, reduce recurrences and increase overall survival.

**Keywords:** primary mammary angiosarcoma, radical mastectomy, radiotherapy, chemotherapy, multimodal treatment

## 1 Introduction

Angiosarcoma (AS) is a rare aggressive tumor which arises from endothelial cells lining vascular structures<sup>[1,2]</sup>. Breast is one of the most common primary sites of angiosarcoma<sup>[3]</sup>. Mammary AS accounts for 1% of all soft tissue tumors<sup>[4,5]</sup> and 0.04% of all primary breast tumors<sup>[4,6-11]</sup>. According to the etiology, angiosarcoma of the breast can be primary and secondary<sup>[12]</sup>. Secondary tumors are associated with chronic lymphoedema in the upper limb after axillary lymph-node dissection and radiotherapy in patients with mammary carcinoma. The condition is known as Stewart-Treves syndrome<sup>[4,8,13,14]</sup>. Secondary angiosarcoma is also considered a complication from radiotherapy and breast-conserving surgery (BCS) in patients with breast carcinoma<sup>[15]</sup>. Primary mammary AS is usually found in young patients (20-50 years) with no history of breast carcinoma<sup>[16-19]</sup>. Secondary AS is found in older patients (67-71 years), usually 5 to 10 years

after radiotherapy for breast carcinoma<sup>[4,20-22]</sup>.

## 2 Clinical case

We report a case of primary angiosarcoma of the breast in 48-year-old woman. Three years prior to admission to the hospital the woman noticed a lump in the right mammary gland, which slowly had enlarged. In the last three months the lesion had enlarged more rapidly and reached the skin with ulcer formation. The woman was admitted to the University Hospital in Ruse with severe bleeding from the ulcerated area. On examination, the right mammary gland was three times larger than the left one, with bluish colour and palpable firm tumor mass. In the outer upper quadrant of the affected breast the skin was ulcerated and bleeding. On palpation, right axillary lymph nodes were enlarged but painless. Right radical mastectomy was performed with axillary lymph-node dissection. Chest and abdominal CT scan revealed bilateral pneumofibrotic changes in dorsobasal areas of the lungs, no pathological mediastinal and axillary lymphadenopathy, no pleural effusions. In 8th segment of the liver, oval shaped metastasis was found.

Gross examination of the resected breast showed no evidence of mammary gland parenchyma. Subcutaneously, a cavity, 13 cm in diameter was found. It was filled with dark red blood and blood clots. The nipple was not affected. Histology revealed a tumor composed of anastomosing densely packed vascular spaces of variable sizes,

Received: January 16, 2020 Accepted: March 23, 2020 Published: March 26, 2020

\* Correspondence to: Lena P. Marinova, Department of Radiotherapy, Oncology center, Ruse, Bulgaria; Email: rad\_marinova@abv.bg

<sup>1</sup> Department of Radiotherapy, Oncology center, Ruse, Bulgaria

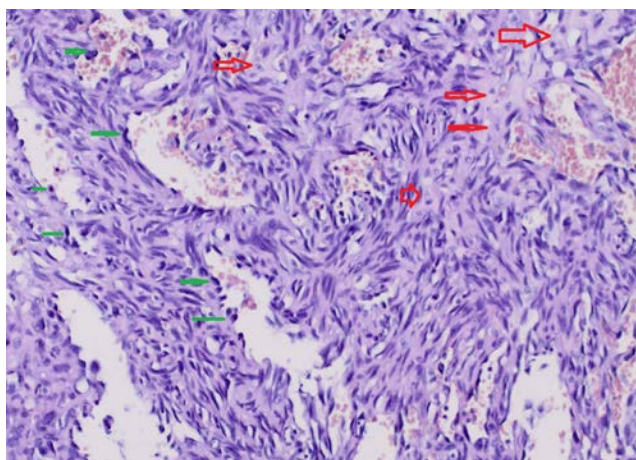
<sup>2</sup> Department of Clinical pathology, Oncology center, Ruse, Bulgaria

<sup>3</sup> Department of General and Clinical Pathology, Forensic Science and Deontology, Medical University, Varna, Bulgaria

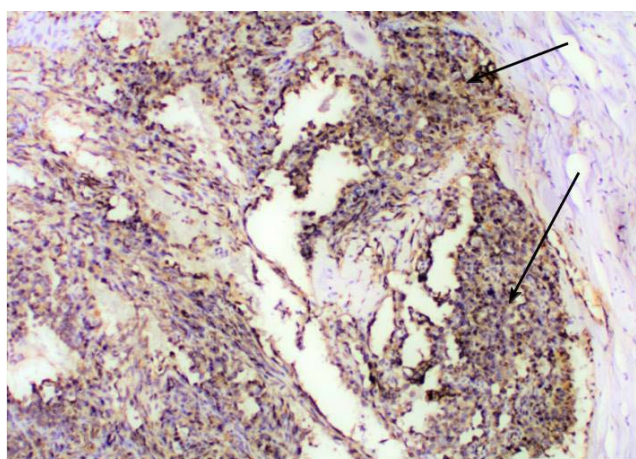
**Citation:** Marinova L, Yordanova BG and Malinova DV. Primary angiosarcoma of the breast: A clinical case and review of the literature. *Curr Cancer Rep*, 2020, 2(1): 28-33.

**Copyright:** © 2020 Lena P. Marinova, et al. This is an open access article distributed under the terms of the [Creative Commons Attribution License](https://creativecommons.org/licenses/by/4.0/), which permits unrestricted use, distribution, and reproduction in any medium, provided the original author and source are credited.

lined with atypical endothelial cells with severe nuclear polymorphism and hyperchromasia, prominent nucleoli and atypical mitotic figures. Intraluminal papillary projections composed of endothelial cells were found, as well as solid areas of spindle shaped cells between the described vascular spaces (Figure 1). Histological examination of the resected axillary lymph nodes showed sinus histiocytosis. The final diagnosis was angiosarcoma of the right mammary gland, grade 3 (G3). Immunohistochemical study revealed a neoplasm positive for CD34 antibody, confirming the vascular nature of the tumor (Figure 2). The epithelial marker, Cytokeratin 1/3, was negative (Figure 3). Estrogen (ER) was negative (Figure 4) and Progesteron (PR) was negative (Figure 5).

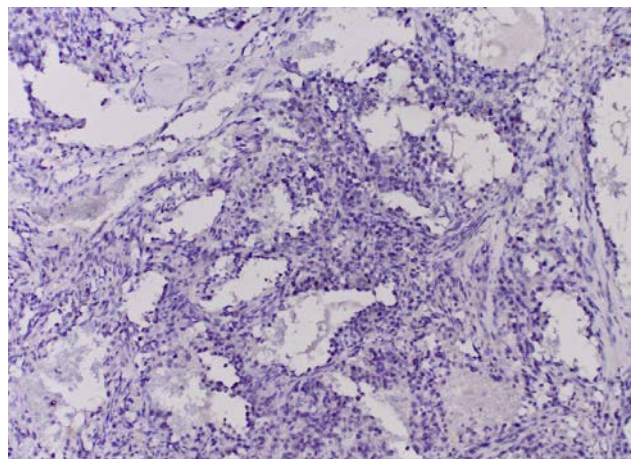


**Figure 1.** Mammary angiosarcoma (G3) composed of atypical polygonal (red arrow) and spindle shaped endothelial cells with hyperchromatic nuclei (green arrow), H & E, ( $\times 40$ )

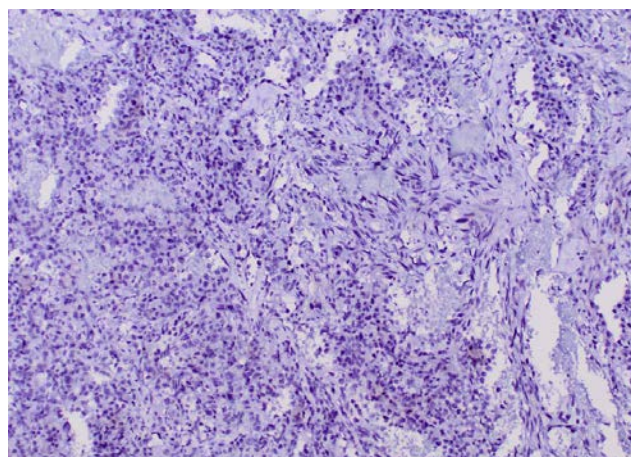


**Figure 2.** Mammary angiosarcoma (G3). Immunohistochemical study showed positivity for CD34 endothelial marker ( $\times 40$ )

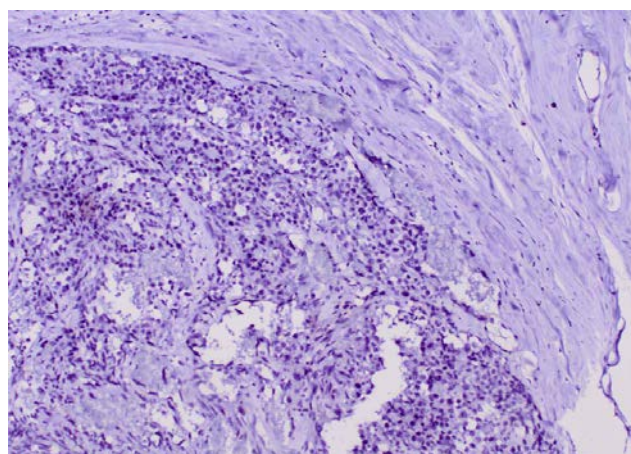
After the surgery, the woman was assessed for chemotherapy, which was not carried out, due to a deterioration in her condition. Within six months the dis-



**Figure 3.** Mammary angiosarcoma (G3). Tumor cells are negative for AE1/AE3 ( $\times 20$ )



**Figure 4.** Mammary angiosarcoma (G3). Tumor cells are negative for ER ( $\times 20$ )



**Figure 5.** Mammary angiosarcoma (G3). Tumor cells are negative for PR ( $\times 20$ )



ease quickly progressed. The patient developed a local relapse in the right chest, metastases in the hilar lymph nodes in the right lung with compression of the right pulmonary artery, pulmonary metastases, hepatic metastases, bone and brain metastases. The patient succumbed to her disease eight months after the surgery.

### 3 Discussion

The first case of primary angiosarcoma of the breast is published in 1907 by Borrmann and the first case of secondary mammary angiosarcoma is described by Body *et al.* in 1987<sup>[7,20,21]</sup>. Primary AS of the breast is aggressive tumor with high risk of local recurrence and distant metastases<sup>[8,22,23]</sup>. The lack of prospective randomized studies on the role of the systematic therapeutic approach in the literature is due to the rarity of this tumor. The major problems concerning AS are: (1) difficult histological diagnosis and broad differential diagnosis, requiring immunohistochemical analysis; (2) choosing the most reliable multimodal treatment for these patients.

Clinically, patients with primary mammary AS present with rapidly growing painless palpable tumor mass<sup>[24,25]</sup>. In 2% of the cases patients present with increased breast volume and bluish red coloration of the overlying skin<sup>[13,25]</sup>. Usually, the axillary lymph nodes are not enlarged. In the majority of cases published in the literature, the size of the tumor is more than 4 cm. in diameter<sup>[26]</sup>.

Preoperative diagnosis with fine needle biopsy (FNB) is difficult. Chen *et al.* reported false negative diagnosis after FNB in 37% of the cases<sup>[3]</sup>. Differential diagnosis includes hemangioma, benign vascular proliferation<sup>[27]</sup>, hamartoma<sup>[28]</sup>, stromal hyperplasia, phylloides tumor, stromal sarcoma, metaplastic carcinoma, other sarcomas, like fibrosarcoma and liposarcoma<sup>[26,29]</sup>. Large-core biopsy might facilitate the accurate diagnosis, but such a biopsy is difficult to perform due to the vascular nature of the neoplasm. Final diagnosis usually is made after surgical resection and histological examination of the specimen. Three main histopathological patterns of mammary AS have been described according to the grade of differentiation:

Grade I (G1) is characterized by anastomosing vascular channels, lined by a single layer of endothelial cells; these channels dissect through the stroma causing distortion but little destruction of the preexisting lobules and ducts.

Grade II (G2) is similar to grade II tumors but with increased mitoses, endothelial tufting and foci of papillary formations and/or solid growth pattern.

Grade III (G3) is characterized by marked pleomorphism, mitoses, necrosis and solid growth, may show epithelioid and spindled cytology (Figure 1)<sup>[31,32]</sup>.

Different areas from one and the same tumor can be with different tumor grades. The degree of differentiation can't be defined properly on core-biopsy<sup>[1]</sup>.

Immunohistochemical analysis can prove the endothelial differentiation of the tumor cells. CD31 is one of the most sensitive and specific markers for endothelial cells. Tumor cells are also positive for Factor VIII, Fli1 and CD34<sup>[13,31,33-35]</sup>. In some cases papillary proliferations are found in the vascular spaces and these areas can resemble ductal carcinoma in situ. Estrogen receptors are reported to be negative in most cases<sup>[26,36]</sup>. In the case reported here, estrogen and progesterone receptors were both negative (Figure 4 and Figure 5).

Soft tissue sarcomas depending on histology and G are aggressive neoplasms with varying degrees of local invasiveness and risk of hematogenous dissemination. In the presented clinical case, there is an aggressive G3 sarcoma with high metastatic potential.

There is no optimal treatment for breast angiosarcoma due to the rarity of this tumor<sup>[15]</sup>. Similar to other soft tissue sarcomas, prognostic factors include tumor size, degree of differentiation, margin status at the time of surgery<sup>[15,37,38]</sup>. Disease recurrence rate increases in the case of residual tumor and grade 3 AS<sup>[21,37,39,40]</sup>. Three studies reported longer disease free survival (DFS) in grade I and grade II tumors, compared to grade III neoplasms<sup>[2,37,41]</sup>. It has been reported that the five year survival rate in well differentiated AS is 76%, and in poorly differentiated angiosarcomas, it is 15%<sup>[13]</sup>.

#### 3.1 Surgical treatment

Mammary AS is treated surgically, but also with chemotherapy and radiotherapy. The treatment lacks uniformity and criteria for surgery and adjuvant therapy are still discussed in the literature<sup>[42]</sup>. Breast-conserving therapy is recommended for small, grade I tumors, if there is a chance of achieving negative surgical margins<sup>[32]</sup>. Some authors recommend aggressive surgical treatment with removal of muscle tissue<sup>[21,22]</sup>. Radical mastectomy alone or with axillary lymph-node dissection is the preferred surgical treatment<sup>[14]</sup>. However, nodal metastases are rare in AS and the necessity for nodal dissection is obscure<sup>[15]</sup>. A study from 2017 reported worse overall survival (OS) in patients with primary AS who received mastectomy, when compared with patients who received breast-conserving surgery<sup>[43]</sup>.

#### 3.2 Adjuvant chemotherapy and radiotherapy

Chemotherapy and radiotherapy have been used in the adjuvant setting of mammary AS, but these therapies need

further examination and clear criteria<sup>[12,29,38,44]</sup>. Literature lacks prospective randomized trials on the effect of adjuvant chemotherapy and radiotherapy and they are used only for tumors with high risk of recurrence<sup>[13]</sup>. Radiotherapy is based on tumor characteristics and the type of surgical treatment<sup>[2]</sup>. Radiotherapy is beneficial for patients with histologically positive surgical margins after mastectomy<sup>[45]</sup>. In two studies, a benefit to the 5 and 10 year recurrence free survival (RFS), disease free survival (DFS) and overall survival (OS) was observed following radiation treatment<sup>[46,47]</sup>. Some authors report that Anthracycline-based therapy can improve DFS and OS<sup>[48]</sup>. A meta-analysis of patients treated with Doxorubicin and a randomized trial of Epirubicin plus Ifosfamide demonstrated longer DFS and OS<sup>[49,50]</sup>. In two studies, adjuvant chemotherapy had no effect on DFS or OS<sup>[2,51]</sup>. In the majority of the reported cases patients are treated with Cyclophosphamid, Anthracycline or alkylating agents in combination with pyrimidine analog<sup>[24]</sup>. Paclitaxel is proven to be active and is commonly used in advanced angiosarcomas from different primary tumor sites<sup>[51-53]</sup>. T Sher *et al.* report that anthracycline-ifosfamide and gemcitabine-taxane chemotherapy regimens appear to be highly active in 48% of the cases<sup>[36]</sup>.

### 3.3 Neoadjuvant chemotherapy and radiotherapy

Primary mammary AS can spread through blood to lungs, liver, skin and contralateral mammary gland<sup>[13]</sup>. Retrospective analysis of 41 patients with metastatic angiosarcomas from different primary tumor sites showed an improved OS from 10.4 to 23.7 months with taxane based regimens compared to non-taxane based adjuvant chemotherapy<sup>[54]</sup>. Paclitaxel therapy shows promise in the treatment of angiosarcoma<sup>[55]</sup>.

Immunotherapy with IL-2 (interleukin-2) is also part of the treatment<sup>[43]</sup>. Different drugs that suppress endothelial proliferation can be used<sup>[13]</sup>. There are few papers that have examined the use of angiogenesis inhibitors like bevacizumab<sup>[55,56]</sup> and rapamycin<sup>[18]</sup>.

## 4 Conclusion

The reported primary AS of the breast is a rare aggressive tumor with bad prognosis. The final diagnosis is based on specific histological criteria and immunohistochemical analysis. Prospective randomized trials are requested to reach a consensus on the optimal multimodal treatment. The gold-standard treatment in patients affected by primary angiosarcoma of the breast is surgery. Adjuvant chemotherapy and radiotherapy are recommended in G3 tumors with high risk of recurrence

and distant metastases. The presented primary AS of the breast is a rare aggressive G3 sarcoma with high metastatic potential.

## References

- [1] Donnell RM, Rosen PP, Lieberman PH, *et al.* Angiosarcoma and other vascular tumors of the breast. *The American Journal Surgical Pathology*, 1981, **5**: 629-642. <https://doi.org/10.1097/00000478-198110000-00005>
- [2] Rosen PP, Kimmel M and Ernsberger D. Mammary angiosarcoma: the prognostic significance of tumor differentiation. *Cancer*, 1988, **62**(10): 2145-2151. [https://doi.org/10.1002/1097-0142\(19881115\)62:10<2145::AID-CNCR2820621014>3.0.CO;2-O](https://doi.org/10.1002/1097-0142(19881115)62:10<2145::AID-CNCR2820621014>3.0.CO;2-O)
- [3] Chen KT, Kirkegaard DD and Bocian JJ. Angiosarcoma of the breast. *Cancer*, 1980, **46**(2): 368-371. [https://doi.org/10.1002/1097-0142\(19800715\)46:2<368::AID-CNCR2820460226>3.0.CO;2-E](https://doi.org/10.1002/1097-0142(19800715)46:2<368::AID-CNCR2820460226>3.0.CO;2-E)
- [4] Hui A, Henderson M, Speakman D, *et al.* Angiosarcoma of the breast: a difficult surgical challenge. *The Breast*, 2012, **21**(4): 584-589. <https://doi.org/10.1016/j.breast.2012.01.001>
- [5] May DS and Stroup NE. The incidence of sarcomas of the breast among women in the United States, 1973-1986. *Plastic and Reconstructive Surgery*, 1991, **87**(1): 193-194. <https://doi.org/10.1097/00006534-199101000-00045>
- [6] Hodgson NC, Bowen-Wells C, Moffat F, *et al.* Angiosarcoma of the breast: a review of 70 cases. *American Journal of Clinical Oncology*, 2007, **30**(6): 570-573. <https://doi.org/10.1097/COC.0b013e3181131d62>
- [7] Kaklamanos IG, Birbas K, Syrigos KN, *et al.* Breast angiosarcoma that is not related to radiation exposure: a comprehensive review of the literature. *Surgery Today*, 2011, **41**: 163-168. <https://doi.org/10.1007/s00595-010-4341-x>
- [8] Torres KE, Ravi V, Kin K, *et al.* Long-term outcomes in patients with radiation-associated angiosarcomas of the breast following surgery and radiotherapy for breast cancer. *Annals Surgical Oncology*, 2013, **20**: 1267-1274. <https://doi.org/10.1245/s10434-012-2755-y>
- [9] Vorburger SA, Xing Y, Hunt KK, *et al.* Angiosarcoma of the breast. *Cancer*, 2005, **104**(12): 2682-2688. <https://doi.org/10.1002/cncr.21531>
- [10] Desbiens C, Hogue JC and Lvesque Y. Primary Breast Angiosarcoma. *Oncological Medicine*, 2011, Article ID 517047, 5 pages. <https://doi.org/10.1155/2011/517047>
- [11] Aydogdu M and Trams G. Angiosarcoma of the breast after conservatively operated breast carcinoma - a sequelae of adjuvant radiotherapy? *Geburtshilfe Frauenheilkd*, 1996, **56**(1): 60-62. <https://doi.org/10.1055/s-2007-1023251>
- [12] Lim RF and Goei R. Angiosarcoma of the Breast, *RadioGraphics (Best Cases from the AFIP)*, 2007, **27**(supple 1): S125-S130. <https://doi.org/10.1148/rg.27si075016>

- [13] Bhosale SJ, Kshirsagar AY, Patil MV, *et al.* Primary angiosarcoma of breast: A case report. *International Journal of Surgery Case Reports*, 2013, **4**(4): 362-364. <https://doi.org/10.1016/j.ijscr.2013.01.016>
- [14] Kunkiel M, Maczkiewicz M, Jagieo-Gruszfeld A, *et al.* Primary angiosarcoma of the breast-series of 11 consecutive cases-a single-centre experience. *Current Oncology*, 2018, **25**(1): 50-53. <https://doi.org/10.3747/co.25.3816>
- [15] Arora TK, Terracina KP, Soong J, *et al.* Primary and secondary angiosarcoma of the breast. *Gland Surgery*, 2014, **3**(1): 28-34. <https://www.ncbi.nlm.nih.gov/pmc/articles/PMC4115777/>
- [16] Wang XY, Jakowski J, Tawfik OW, *et al.* Angiosarcoma of the breast: a clinicopathologic analysis of cases from the last 10 years. *Annals of Diagnostic Pathology*, 2009, **13**(3): 147-150. <https://doi.org/10.1016/j.amndiagpath.2009.02.001>
- [17] Scow JS, Reynolds CA, Degnim AC, *et al.* Primary and secondary angiosarcoma of the breast: the Mayo Clinic experience. *Journal of Surgical Oncology*, 2010, **101**(5): 401-407. <https://doi.org/10.1002/jso.21497>
- [18] Vemulapalli S, Mita A, Alvarado Y, *et al.* The emerging role of mammalian target of rapamycin inhibitors in the treatment of sarcomas. *Targeted Oncology*, 2011, **6**(1): 29-39. <https://doi.org/10.1007/s11523-011-0179-4>
- [19] Iacoponi S, Calleja J, Hernandez G, *et al.* Primary breast angiosarcoma in a young woman. *International Journal of Surgery Case Reports*, 2016, **24**: 101-103. <https://doi.org/10.1016/j.ijscr.2016.05.015>
- [20] Seinen JM, Styring E, Verstappen V, *et al.* Radiation-associated angiosarcoma after breast cancer: high recurrence rate and poor survival despite surgical treatment with R0 resection. *Annals of Surgical Oncology*, 2012, **19**: 2700-2706. <https://doi.org/10.1245/s10434-012-2310-x>
- [21] Jallali N, James S, Searle A, *et al.* Surgical management of radiation-induced angiosarcoma after breast conservation therapy. *The American Journal Surgery*, 2012, **203**(2): 156-161. <https://doi.org/10.1016/j.amjsurg.2010.12.011>
- [22] Morgan EA, Kozono DE, Wang Q, *et al.* Cutaneous radiation-associated angiosarcoma of the breast: poor prognosis in a rare secondary malignancy. *Annals of Surgical Oncology* volume, 2012, **19**: 3801-3808. <https://doi.org/10.1245/s10434-012-2563-4>
- [23] Nicolas MM, Nayar R, Yeldandi A, *et al.* Pulmonary metastasis of a postradiation breast epithelioid angiosarcoma mimicking adenocarcinoma. *Acta Cytological*, 2006, **50**(6): 672-676. <https://doi.org/10.1159/000326039>
- [24] Johnson CM and Garguilo GA. Angiosarcoma of the breast: a case report and literature review. *Current Surgery*, 2002, **59**(5): 490-494. [https://doi.org/10.1016/S0149-7944\(02\)00629-3](https://doi.org/10.1016/S0149-7944(02)00629-3)
- [25] Georgiannos SN and Sheaff M. Angiosarcoma of the breast: a 30 year perspective with an optimistic outlook. *British Journal of Plastic Surgery*, 2003, **56**(2): 129-134. [https://doi.org/10.1016/S0007-1226\(03\)00025-0](https://doi.org/10.1016/S0007-1226(03)00025-0)
- [26] Ohta M, Tokuda Y and Kuge S. A case of angiosarcoma of the breast. *Japanese Journal of Surgical Oncology*, 1997, **27**(2): 91-94. <https://doi.org/10.1093/jjco/27.2.91>
- [27] Rosen PP. Vascular tumors of the breast: III. The American Journal of Surgical Pathology, 1985, **9**: 652-658. <https://doi.org/10.1097/00000478-198509000-00004>
- [28] Fisher CJ, Hanby AM, Robinson L, *et al.* Mammary hamartoma- a review of 35 cases. *Histopathology*, 1992, **20**(2): 99-106. <https://doi.org/10.1111/j.1365-2559.1992.tb00938.x>
- [29] Zelek L, Llombart-Cussac A and Terrier P. Prognostic factors in primary breast sarcomas: a series of patients with long-term follow-up. *Journal of Clinical Oncology*, 2003, **21**(13): 2583-2588. <https://doi.org/10.1200/JCO.2003.06.080>
- [30] Cornelis A, Verjans M, Van Den Bosch T, *et al.* Efficacy and safety of direct and frontal macrobiopsies in breast cancer. *European Journal of Cancer Prevention*, 2009, **18**(4): 280-284. <https://doi.org/10.1097/CEJ.0b013e328329d885>
- [31] Jagtap SV, Shukla D, Bonde VS, *et al.* Primary angiosarcoma of the breast: an uncommon histopathological subtype. *Journal of Clinical and Diagnostic Research*, 2015, **9**(12): 5-6. <https://doi.org/10.7860/JCDR/2015/15855.6885>
- [32] Glazebrook KN, Magut MJ and Reynolds C. Angiosarcoma of the Breast. *American Journal of Roentgenology*, 2008, **190**(2): 533-538. <https://doi.org/10.2214/AJR.07.2909>
- [33] Hart J and Mandavilli S. Epithelioid angiosarcoma: a brief diagnostic review and differential diagnosis. *Archives of Pathology and Laboratory Medicine*, 2011, **135**(2): 268-272. <https://www.archivesofpathology.org/doi/full/10.1043/1543-2165-135.2.268>
- [34] Folpe AL, Chand EM, Goldblum JR, *et al.* Expression of Fli-1, a nuclear transcription factor, distinguishes vascular neoplasms from potential mimics. *The American Journal of Surgical Pathology*, 2001, **25**(8): 1061-1066. <https://doi.org/10.1097/00000478-200108000-00011>
- [35] Bennani A, Chbani L, Lamchahab M, *et al.* Primary angiosarcoma of the breast: a case report. *Diagnostic Pathology*, 2013, **8**: 66. <https://doi.org/10.1186/1746-1596-8-66>
- [36] Sher T, Hennessy BT, Valero V, *et al.* Primary angiosarcomas of the breast. *Cancer*, 2007, **110**(1): 173-178. <https://doi.org/10.1002/cncr.22784>
- [37] Bousquet G, Confavreux C, Magne N, *et al.* Outcome and prognostic factors in breast sarcoma: a multicenter study from the rare cancer network. *Radiotherapy Oncology*, 2007, **85**(3): 355-3561. <https://doi.org/10.1016/j.radonc.2007.10.015>
- [38] Horisawa N, Adachi Y, Sawaki M, *et al.* A case of radiation-associated angiosarcoma after breast cancer. *Surgical Case Reports*, 2018, **4**(1): 131. <https://doi.org/10.1186/s40792-018-0538-9>

- [39] Adem C, Reynolds C, Ingle JN, *et al.* Primary breast sarcoma: clinicopathologic series from the Mayo Clinic and review of the literature. *British Journal of Cancer*, 2004, **91**(2): 237-241.  
<https://www.ncbi.nlm.nih.gov/pmc/articles/PMC2409972/>
- [40] Barrow BJ, Janjan NA, Gutman H, *et al.* Role of radiotherapy in sarcoma of the breast—a retrospective review of the M.D. Anderson experience. *Radiotherapy Oncology*, 1999, **52**(2): 173-178.  
[https://doi.org/10.1016/S0167-8140\(99\)00070-5](https://doi.org/10.1016/S0167-8140(99)00070-5)
- [41] Luini A, Gatti G, Diaz J, *et al.* Angiosarcoma of the breast: the experience of the European Institute of Oncology and a review of the literature. *Breast Cancer Research and Treatment*, 2007, **105**: 81-85.  
<https://doi.org/10.1007/s10549-006-9429-z>
- [42] Ayadi MA, Mansouri H, Safta IB, *et al.* Primary breast angiosarcoma: Prognostic and therapeutic approach. *Journal of Dental and Medical Sciences*, 2018, **17**(9): 86-91.  
<https://pdfs.semanticscholar.org/28c1/e4f3d2eb4ba6d6c3c657622ad54579325d6a.pdf>
- [43] Yin M, Wang W, Drabick J, *et al.* Prognosis and Treatment of Non-Metastatic Primary and Secondary Breast Angiosarcoma: A Comparative Study. *BMC Cancer*, 2017, **17**(1): 295.  
<https://doi.org/10.1186/s12885-017-3292-7>
- [44] Gutman H, Pollock RE, Ross MI, *et al.* Sarcoma of the breast: implications for extent of therapy. The M. D. Anderson experience, *Surgery*, 1994, **116**(3): 505-509.
- [45] McGowan TS, Cummings BJ, O’Sullivan B, *et al.* An analysis of 78 breast sarcoma patients without distant metastases at presentation. *International Journal of Radiation Oncology Biology Physics*, 2000, **46**(2): 383-390.  
[https://doi.org/10.1016/S0360-3016\(99\)00444-7](https://doi.org/10.1016/S0360-3016(99)00444-7)
- [46] Losanoff JE, Jaber S, Esuba M, *et al.* Primary angiosarcoma of the breast: do enlarged axillary nodes matter? *The Breast Journal*, 2006, **12**(4): 371-374.  
<https://doi.org/10.1111/j.1075-122X.2006.00280.x>
- [47] Johnstone PA, Pierce LJ, Merino MJ, *et al.* Primary soft tissue sarcomas of the breast: local-regional control with post-operative radiotherapy. *International Journal of Radiation Oncology Biology Physics*, 1993, **27**(3): 671-675.  
[https://doi.org/10.1016/0360-3016\(93\)90395-C](https://doi.org/10.1016/0360-3016(93)90395-C)
- [48] Fodor J, Orosz Z, Szab E, *et al.* Angiosarcoma after conservation treatment for breast carcinoma: our experience and a review of the literature. *Journal of the American Academy of Dermatology*, 2006, **54**(3): 499-504.  
<https://doi.org/10.1016/j.jaad.2005.10.017>
- [49] Pervaiz N, Colterjohn N, Farrokhyar F, *et al.* A systematic meta-analysis of randomized controlled trials of adjuvant chemotherapy for localized resectable soft-tissue sarcoma. *Cancer*, 2008, **113**(3): 573-581.  
<https://doi.org/10.1002/cncr.23592>
- [50] Frustaci S, Gherlinzoni F, De Paoli A, *et al.* Adjuvant chemotherapy for adult soft tissue sarcomas of the extremities and girdles: results of the Italian randomized cooperative trial. *Journal of Clinical Oncology*, 2001, **19**(5): 1238-1247.  
<https://doi.org/10.1200/JCO.2001.19.5.1238>
- [51] Baum JK, Levine AJ and Ingold JA. Angiosarcoma of the breast with report of unusual site of first metastasis. *Journal of Surgical Oncology*, 1990, **43**(2): 125-130.  
<https://doi.org/10.1002/jso.2930430213>
- [52] Chiarelli A, Boccone P, Goia F, *et al.* Gingival metastasis of a radiotherapy-induced breast angiosarcoma: diagnosis and multidisciplinary treatment achieving a prolonged complete remission. *Anticancer Drugs*, 2012, **23**(10): 1112-1117.  
<https://doi.org/10.1097/CAD.0b013e3283579e0d>
- [53] Kim EK, Park IS, Sohn BS, *et al.* Angiosarcomas of the bilateral breast and heart: which one is the primary site? *The Korean Journal of Internal Medicine*, 2012, **27**(2): 224-228.  
<https://doi.org/10.3904/kjim.2012.27.2.224>
- [54] Hirata T, Yonemori K, Ando M, *et al.* Efficacy of taxane regimens in patients with metastatic angiosarcoma. *European Journal of Dermatology*, 2011, **21**(4): 539-545.  
<https://doi.org/10.1684/ejd.2011.1403>
- [55] Penel N, Bui BN and Bay JO. Phase II trial of weekly paclitaxel for unresectable angiosarcoma: the ANGIOTAX study. *Journal of Clinical Oncology*, 2008, **26**(32): 5269-5274.  
<https://doi.org/10.1200/JCO.2008.17.3146>
- [56] Rosen A, Thimon S, Ternant D, *et al.* Partial response to bevacizumab of an extensive cutaneous angiosarcoma of the face. *British Journal of Dermatology*, 2010, **163**(1): 225-227.  
<https://doi.org/10.1111/j.1365-2133.2010.09803.x>
- [57] Azizi AA, Haberler C, Czech T, *et al.* Vascular-endothelial-growth-factor (VEGF) expression and possible response to angiogenesis inhibitor bevacizumab in metastatic alveolar soft part sarcoma. *The Lancet Oncology*, 2006, **7**(6): 521-523.  
[https://doi.org/10.1016/S1470-2045\(06\)70729-X](https://doi.org/10.1016/S1470-2045(06)70729-X)
- [58] Shih T and Lindley C. Bevacizumab: an angiogenesis inhibitor for the treatment of solid malignancies. *Clinical Therapeutics*, 2006, **28**(11): 1779-1802.  
<https://doi.org/10.1016/j.clinthera.2006.11.015>
- [59] Fuller CK, Charlson JA, Dankle SK, *et al.* Dramatic improvement of inoperable angiosarcoma with combination paclitaxel and bevacizumab chemotherapy. *Journal of the American Academy of Dermatol.* 2010, **63**(4): e83-e84.  
<https://doi.org/10.1016/j.jaad.2009.09.035>
- [60] Park MS, Ravi V and Araujo DM. Inhibiting the VEGF-VEGFR pathway in angiosarcoma, epithelioid hemangioidoma, and hemangiopericytoma/solitary fibrous tumor. *Current Opinion in Oncology*, 2010, **22**(4): 351-355.  
<https://doi.org/10.1097/CCO.0b013e328333aaad4>

(Edited by Snowy Wang)